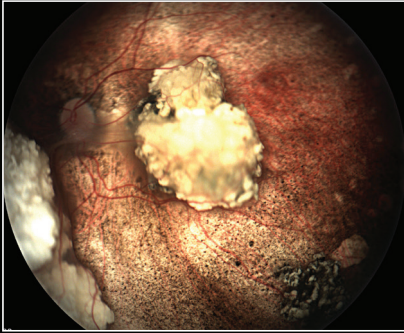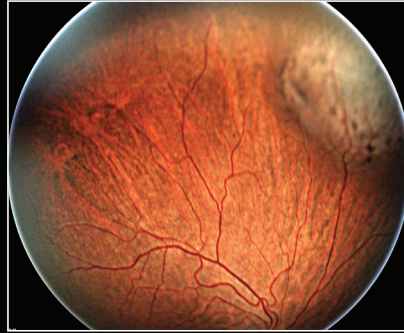
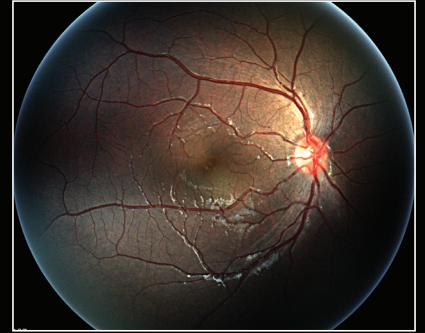


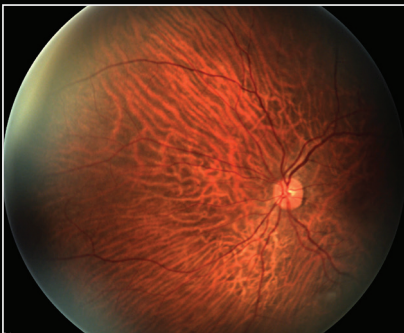
Age: 19 years



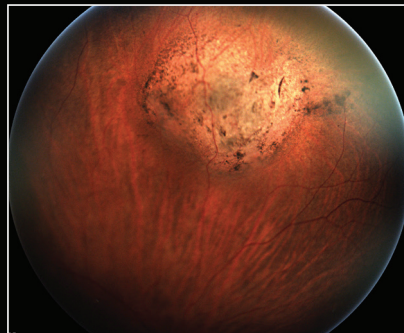
Age: 43 years



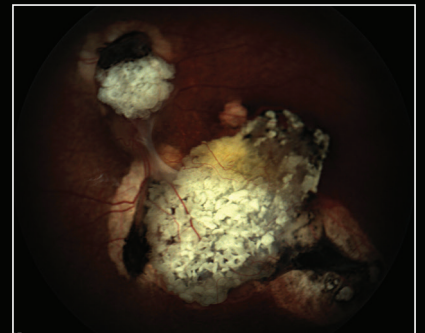
Age: 23 years



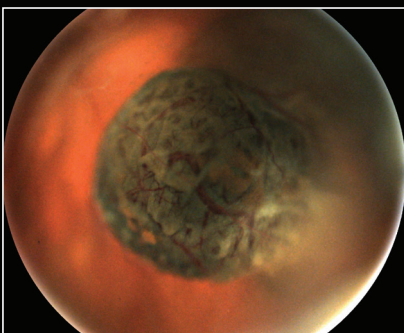
Age: 48 years



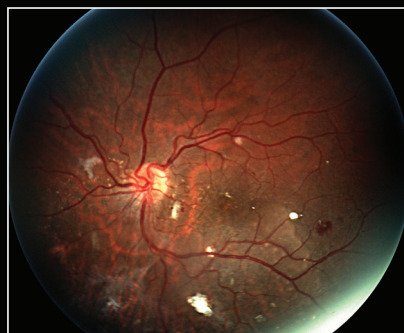Age: 43 years



Age: 24 years



Age: 90 years \*



Age: 23 years

*Except as noted - all patients were phakic and imaged awake.*

*\* patient aphakic*

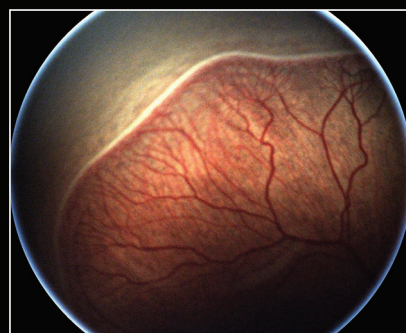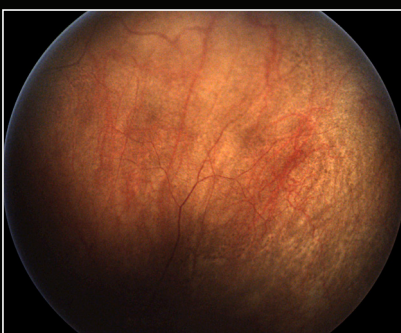
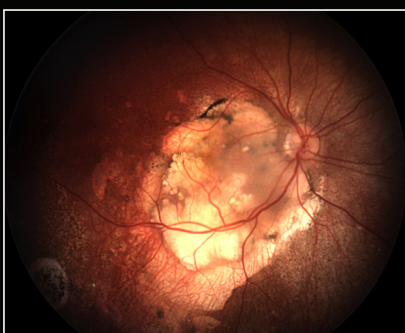
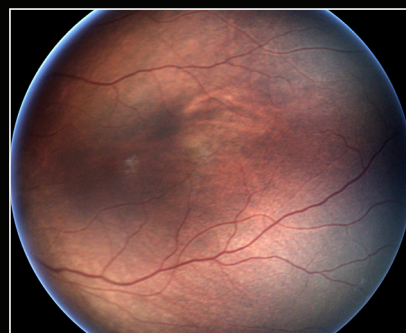
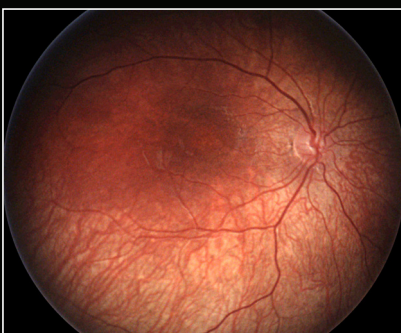
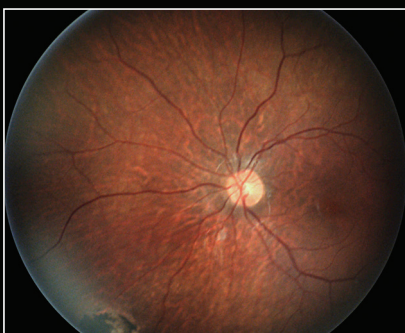
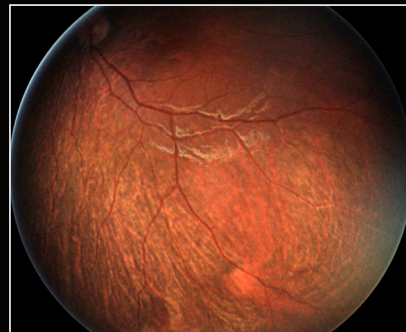
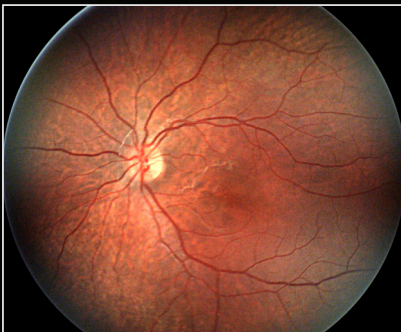

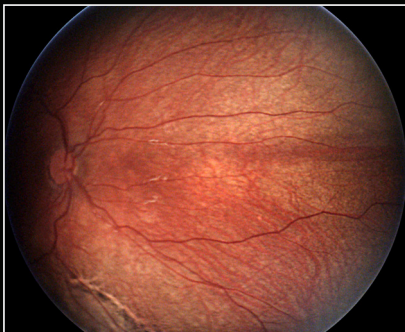
Image Gallery courtesy of Mike Trese, MD  
William Beaumont Hospital  
Royal Oak, Michigan

OPL-0039-3